

Table of Contents

EKG TRACING	1
Figure 1 - EKG Tracing	Error! Bookmark not defined.
STEP 1	1
Rate	1
Figure 2 - Determining the Rate	1
<i>Step 2</i>	2
Rhythm	2
Figure 3 - Determining the Rhythm Source	2
<i>Step 3</i>	2
Axis	2
Figure 4 - The Limb and Augmented Leads in relation to the body	3
Figure 4 - Computing the Axis	4
Figure 5 - All limb and augmented leads	4
STEP 4	5
Precordial Leads	5
Figure 6 - The Precordial Leads	5
STEP 5	5
Hypertrophy	5
Figure 7 - Biphasic P-Waves	6
Figure 8 - RVH	6
Figure 9 - LVH	7
STEP 6	7
Blocks	7
Figure 10 - AV-Block	7
STEP 7	9
Ischemia, Infarct and Injury	9
Transmural Ischemia	9
Sub-Endocardial Ischemia	10
Figure 19 - ST-Segment Depression in subendocardial ischemia	10
<i>Step 8</i>	11
<i>Miscellaneous</i>	11
Ventricular Fibrillation	11
Tachycardia	11
Sinus Tachycardia	12
Digitalis Toxicity	13
Figure 22 - Digitalis Toxicity	14
Hyperkalemia	14
Figure 23 - Peaked-T Waves consistent with Hyperkalemia	14
CREDITS	15
<i>Authors</i>	15
Henry Feldman	15
Mariano Rey, MD	15
<i>Other Contributors</i>	15
Daniel Fisher, MD	15

EKG Tracing

Please refer to the EKG tracing below if you are not familiar with the labeling of the EKG waveforms.

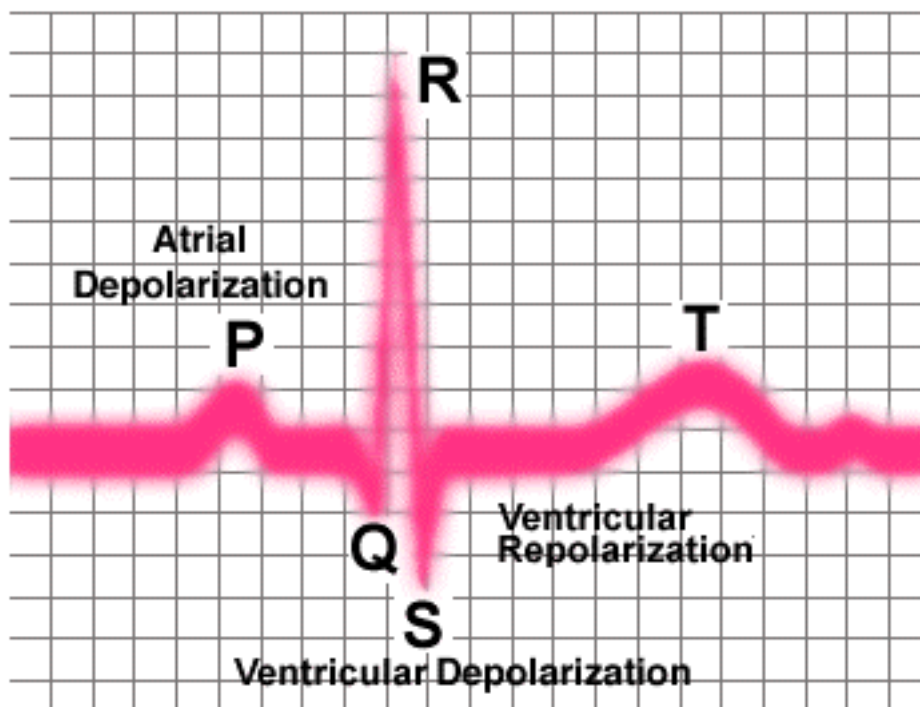


Figure 1- EKG Tracing

Step 1

Rate

The first step is to determine the **RATE**, which can be eyeballed by the following technique. Locate the QRS (*the big spike*) complex that is closest to a dark vertical line. Then count either forward or backwards to the next QRS complex. For each dark vertical line you pass, select the next number off the mnemonic "300-150-100-75-60-50" to estimate the rate in *beats per minute* (BPM).

In other words if you pass 2 lines before the next QRS, the heart rate (HR) would be less than 150. Remember that this is merely an estimate. You should use real measurements to determine the exact HR (for precise measurement: each large box represents 200msec and small boxes represent 40msec). As an example of using the mnemonic, in the segment of the EKG below, start at the QRS that lines up with the vertical line at "0". Now counting back each vertical line to the previous EKG "300-150-100" we notice the HR to be slightly less than 100 (probably around 90-95).

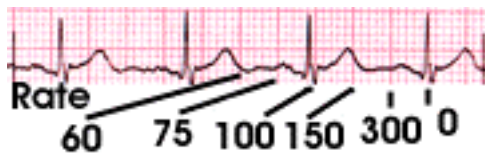


Figure 2 - Determining the Rate

Step 2

Rhythm

Next we need to determine the **RHYTHM** both its *source* and its *regularity*. The prime concern is whether the source of the rhythm is the SA node (sino-atrial) or an ectopic pacemaker. To determine whether the source of the rhythm is "sinus" or an ectopic rhythm, you need to look at the relationship of the P-wave, if present, to the QRS-complex. If there is a P wave before each QRS and the P is in the same direction as the QRS, the rhythm can be said to be sinus. For instance note in the EKG segment below that there is a P-wave before each QRS (highlighted in blue) and that it is pointing up as is the QRS segment.

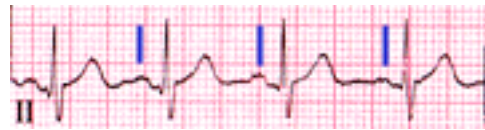


Figure 3 - Determining the Rhythm Source

Also look at the quality and quantity of P-waves before each QRS. There should only be one P-wave before each QRS. The P-wave should be in only one direction, and not biphasic (except for leads V1 and V2). It should also be closer than 200ms to the QRS. The shape of the P-wave should also be gently rounded and not peaked.

Step 3

Axis

Next we need to determine the **AXIS** of the EKG tracing. To do this we need to understand the basic 6 leads and their geometry. The EKG waveform comes from a measurement of surface voltages between 2 leads. A wave that is travelling **towards** the positive (+) lead will inscribe an upwards deflection of the EKG; conversely a wave traveling **away** from the positive lead will inscribe a downward deflection. Waves that are traveling at a **90 degree** angle to a particular lead will create no deflection and is called an **isoelectric** lead.

As an example in the pictures below, a wave travelling from the head to the feet would be shown as an upwards deflection in AVF, since it is going towards the AVF+ lead.

The axis is the sum of the vectors, produced by the ekg leads, to produce a single electrical vector. Remember that a positive signal in Lead-I means that the signal is going right to left; this produces a vector, which if we take all the leads, we can sum. This summed vector should in general be pointing the same direction (down-left) for a normal heart; this makes sense if we think of the electrical conduction system of the heart which sends a signal from the SA node (top right) to the purkinje fibers (bottom left). Don't worry if you still don't get it, we'll give you a visual example further down the page.

There are six basic leads discussed below and 6 precordial leads which will be discussed later. The basic leads consist of leads I, II and III and the augmented leads AVR, AVL and AVF. These are present on the basic 3-lead monitors and also on the 12-lead EKG machines. They consist of leads on

the left and right shoulders and one on the left side of the abdomen (although conceptually they are on the wrists and above the ankle; hence their name "**limb leads**"). A ground lead is placed on the right ankle.

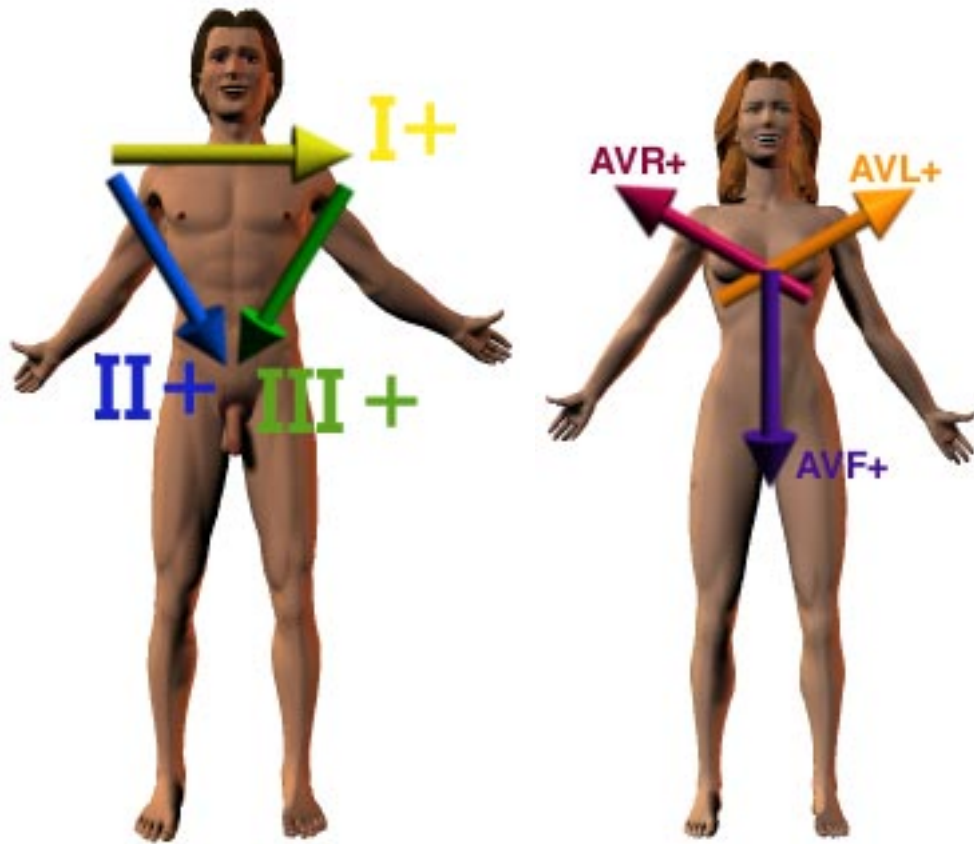


Figure 4 - The Limb and Augmented Leads in relation to the body

You will notice that leads I, II and III form the sides of an equilateral triangle, while AVR, AVL and AVF bisect the vertices of the triangle. The easiest way to figure out the axis is to draw a normal X-Y graph and fill in the quadrants that are represented by each lead with a positive deflection.

There are some tricks to save you time, but first think about a normal EKG plot; in a normal EKG both leads I and AVF will be positive as the signal travels from the SA node (top right of the heart) to the tip of the ventricles (bottom left of the heart). This is a normal axis, and leads us to the rule of thumb, if I and AVF are positive the axis is normal. However, just because this is not the case does not mean that the axis is abnormal! (you need to look at more leads in this case) The normal axis actually allows the signal to travel up to 30° above the X axis and 30° to the left of the Y axis. Let's look at an example below and prove this.

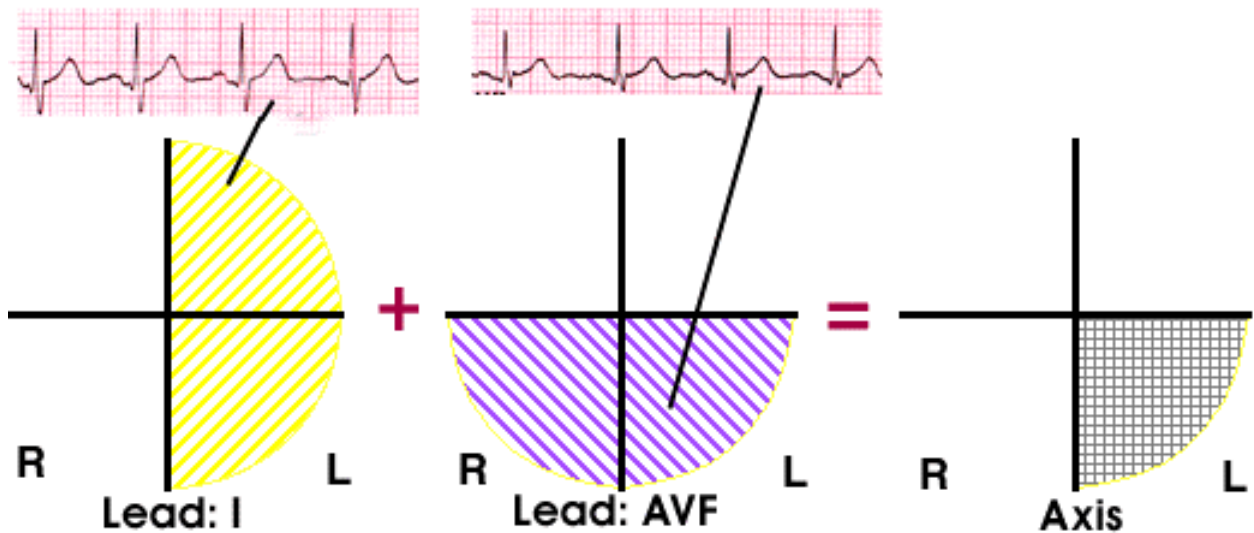


Figure 4 - Computing the Axis

If the axis is not completely in the bottom left (the patient's left) quadrant (i.e. I and AVF are positive), it is simply a matter of using additional leads to determine the axis. Looking at the map of all the leads, we notice that almost 360 degrees of axis are covered. Use the same axis determination method you used with I and AVF.

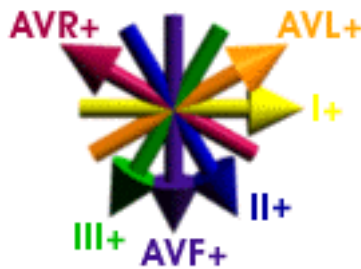


Figure 5 - All limb and augmented leads

Step 4

Precordial Leads

Understanding the precordial leads and how they align with the heart is critical to understanding the EKG. First let's remember how the heart is located in the chest. Note that it sits flat above the diaphragm on the left side of the chest, and is pointed slightly to the left. This is important in understanding how the precordial leads correlate to the actual heart anatomy. We see below the precordial leads in their relationship to the heart and chest anatomy.

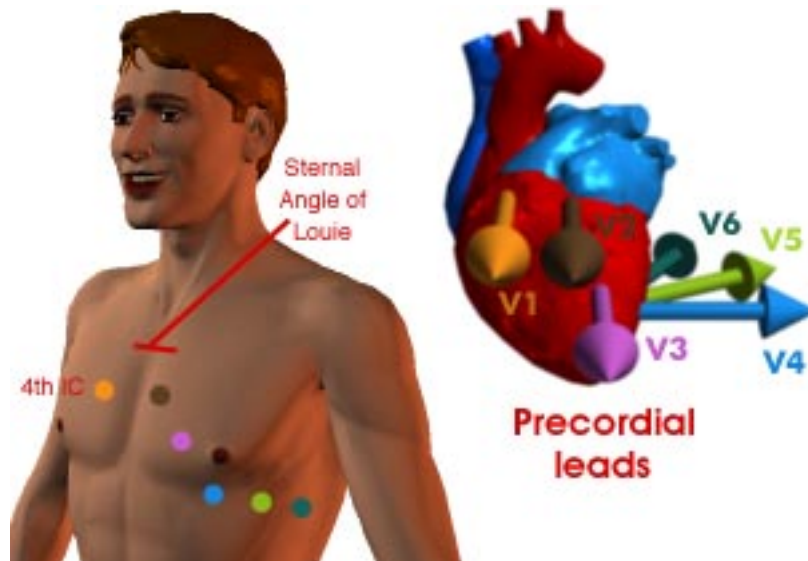


Figure 6 - The Precordial Leads

V1-V2 are over the right ventricle, while V4-V6 primarily are over the left ventricle. V3 is a transitional lead, and is approximately over the intraventricular septum, so it covers some of both ventricles. Remember that the bulk of the left ventricle is posterior, so feel free to create a V7 and V8 to get more information of the left ventricle.

Step 5

Hypertrophy

Hypertrophy is the increase in size of the myocytes in the myocardium, leading to thicker walls. It can be non-pathological, as in the case of people who frequently perform isometric exercise (lifting heavy weights, with the straining and Valsalva maneuver, produces an increased afterload).

Extending this thought, we can see how hypertrophy can occur in the pathological sense by thinking about increased afterload on the heart as in individuals with high blood pressure which causes a left sided afterload increase. Left Sided afterload increases, such as systemic hypertension or aortic stenosis will cause the left ventricle (LV) to expand in response giving Left Ventricular Hypertrophy (LVH).

The right side of the heart can also experience afterload. Increased pressure in the pulmonary vessels will cause an increase in afterload (back-pressure) to the right ventricle (RV), leading to an increase in muscle mass of the RV to compensate, leading to Right Ventricular Hypertrophy (RVH).

As the ventricles, the atria can also become hypertrophic (dilated), which is visualized as changes to the P-wave. The P-wave can become biphasic in **bilateral** atrial hypertrophy. The best place to look for Atrial Hypertrophy is in V1, which is mostly over the right atrium, but being the highest placed lead in the chest also gives left sided information as well). Below we see examples of Right and Left Atrial Hypertrophy showing as biphasic P-waves.

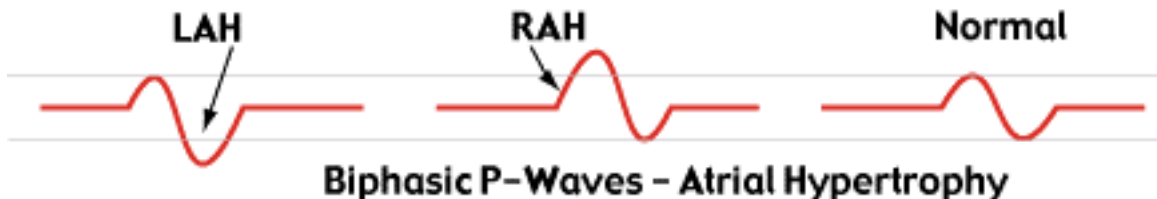


Figure 7 - Biphasic P-Waves

Next we need to examine the ventricles for evidence of hypertrophy there. Since increased muscle mass, logically yields to an increase in the signal (more channels - more current) we would expect to see changes in the QRS complex morphology.

For Right Ventricular Hypertrophy we look at V1 (and less so in V2 and V3) and notice that there is a large R-wave (the normal V1 has a small R with a large S)

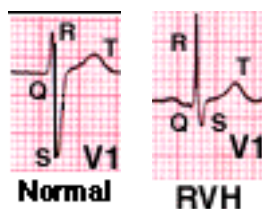


Figure 8 - RVH

This increased R height, will taper down, in V2 and V3. Remember that just because you find RVH doesn't mean that the left ventricle is **also** not hypertrophied, in which case you may not see the normal taper.

In Left Ventricular Hypertrophy (LVH), you will have a large S wave in V1 and a large R wave in V5. The actual criteria, are to add the height of S in V1 and the height of R in V5 (in mm) and if the sum is greater than 35mm, then LVH is probable. For instance in the picture below, we measure the heights (23mm in V1 and 17mm in V5) which total greater than 35mm, so we meet a criterion for LVH.

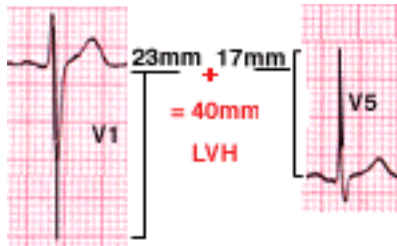


Figure 9 - LVH

Step 6

Blocks

A block is an interruption of the normal flow of an electrical impulse traveling down from the SA node to the ventricles. The blocks can occur in the SA and AV nodes as well as in the bundles.

SA Node Block consists of a failure of the SA node to transmit an impulse, and is usually seen as a complete pause of 1 beat (i.e. a "skipped beat"); if the pause lasts longer or the morphology of the P wave before and after the pause is different, it probably isn't SA block. This block can occur occasionally in normal patients, and should not necessarily be viewed as pathological. Here is an example of SA node block:

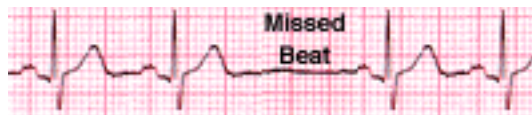


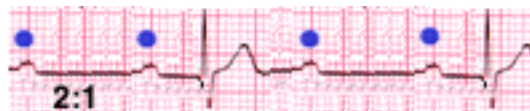
Figure 10 - AV-Block

AV Node Block is a block which delays the electrical impulse as it travels between the atria and the ventricles in the AV node. Since the P-wave represents the activity of the SA node, and the QRS complex represents the activity of the ventricles, it makes sense that the P-R interval represents the delay through the AV node. The criteria for 1° AV node block is a PR interval greater than .2 seconds (200ms or 1 large box). Below we see an example of 1° AV node block.

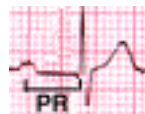

Figure 11 - 1° AV Block - PR Interval 200ms

2° AV Block is where there are more than 1 P-wave preceding each QRS complex. The P-waves are spaced in a regular rhythm, but there is no following ventricular response. We see this below where there is a 2:1 ratio of P-waves to each QRS. Note that other ratios do occur (3:1, 4:1, etc...)



2° AV Block with a 2:1 P-wave ratio

3° Block is a complete block of signals from the atria to the ventricles. As such we would expect complete dissociation between the timing of the P-waves and the QRS complexes. The P-waves will

be in a normal sinus rate, while the QRS's will be either in a **nodal** rhythm (60bpm) or a **ventricular** rhythm (30-40bpm).

However, the key is the lack of synchronization between the two. The lack of synchronization is what determines whether you are in a 2: AV block with a greater than 1:1 ratio or 3: block. It is important to examine the morphology of the QRS complex; if it is a narrow complex, then the origin is likely to be nodal, while a wide complex is likely to be ventricular, although one should also take the rate into account. Below we see an example of 3: Block with a narrow QRS; note the dissociation between the P-wave rate and the QRS rate.

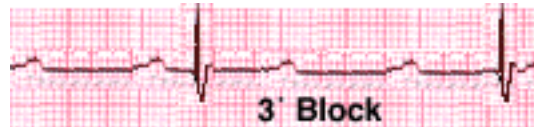


Figure 12 - 3: Block

Bundle Branch Blocks (BB) are blocks within the ventricular bundles, and normally consist of a left or right bundle branch block. You will often hear these erroneously referred to simply as a *left or right "bundle"*, the "block" being superfluous. The blocks can be of the entire ventricular bundle or a fascicle of a given bundle. Here, we are simply going to introduce basic bundle blocks.

The key to recognizing a bundle block is to find a **R-R'** wave; the 2 R waves per complex are really 2 superimposed QRS complexes from each of the ventricles firing separately but very close in time to each other. The criteria consist of a QRS wider than .12 seconds (3mm) and the 2 R waves. In a left bundle block, the left ventricular firing is delayed, while in right bundle block, the right ventricular firing is late.

Below we see examples of Right and Left Bundle Branch Blocks. Note the R-R' complex repeating as well as the QRS complex being wider than 3mm (.12sec). In the Right BBB, the R wave represents the Left Ventricular depolarization, while the R' wave represents the delayed right ventricular response. In the Left BBB, the R wave is the right ventricle and the R' is the left ventricle.

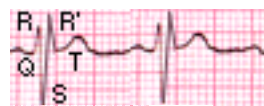


Figure 13 - Right Bundle Branch Block (Lead V1)



Figure 14 - Left Bundle Branch Block (lead V5)

Remember to consider what precordial lead the block is presenting in; if the block morphology presents best in V1-V2, then it is a Right BBB, while a Left BBB pattern is best appreciated in leads V5-V6. Note: the axis will be hard, if not impossible, to accurately determine, as the ventricles are firing asynchronously with each other, altering the normal interventricular phasing.

Step 7

Ischemia, Infarct and Injury

Cardiac Ischemia and infarctions are the most important acute EKG patterns to detect. We will deal with the **life threatening** arrhythmias, such as Asystole, V-Fib and V-Tach in the next section as they are radically different from normal EKG's, and should be handled separately.

When a patient presents to the ER with chest pain, it is important first to immediately perform a **complete** EKG analysis with the preceding steps, unless a life-threatening rhythm is detected, along with the physical examination and clinical assessment of the patient.

Ischemia is when blood flow to the myocardium is insufficient to maintain the metabolic demand of the myocytes. Ischemia can present with symptoms ranging from mild chest discomfort on exertion to the most severe form of ischemia, which results in the crushing chest pain of a infarction; Ischemia may also be silent.

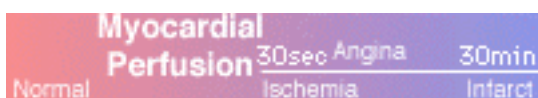

Figure 15 - The Range of Perfusion of the Myocardium

Surprisingly, the QRS is not the most affected part of the EKG waveform in ventricular ischemia. The ST segment is most often affected in ischemic conditions. We will examine the 2 types of ST-segment changes: **elevation** and **depression**. These usually represent transmural ischemia and subendocardial ischemia respectively.

Transmural Ischemia

The hallmark of acute transmural ischemia (across the heart wall from endocardium to epicardium) is the elevation of the ST segment of the EKG. This is visualized by the ST-segment being raised above the isoelectric baseline. This is due to a higher (more positive) resting voltage of ischemic cells, which cause the ST-segment baseline to be more positive (an upwards deflection). This change in the ST segment is mostly localized in the lead most directly overlying the ischemic myocardial area. The etiology of transmural ischemia is the blood supply failing to feed the myocardium. This may lead to **unstable angina**, and should be taken very seriously, as this is the condition that progresses to an **acute MI**. As the ischemia becomes more extensive the ST segment elevation becomes more pronounced.

The lead in which the ST elevation appears, allows you to accurately locate the ischemic or infarcted area of ventricular myocardium. If the elevation appears in inferior leads, this indicates an inferior ischemic/infarcted myocardium; the lateral leads, likewise indicate lateral wall ischemia/infarction.

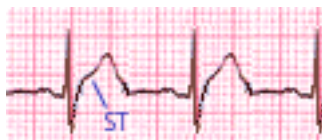

Figure 16 - ST-Segment Elevation

It is important to differentiate pathologic ST segment elevation from non-pathologic **J-point** elevation. J-point elevation is identified by an elevation of the terminal portion of the QRS which then dips back down towards the baseline before rising back up to the ST segment. This is opposed to the pathological ST-elevation which is visualized as the terminal portion of the QRS going directly up to the T-wave.

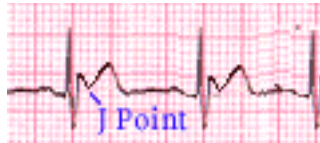

Figure 17 - J-Point Elevation

After the ischemia has progressed to an infarct, and the tissue has scarred, the EKG will show an **inverted T wave**. A pronounced **Q-wave** (not normally present) and loss of all or part of the R wave may also present.

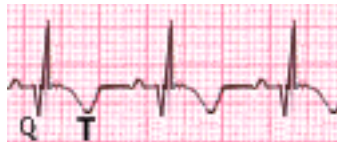

Figure 18 - Q-waves with Inverted T-Waves

Sub-Endocardial Ischemia

Let's look at the progression of ischemia in the subendocardium. Relative decreased flow in the subendocardial regions is a normal consequence of the squeezing of the myocardium, which compresses the blood supply to the endocardium during ventricular systole. However, this can also be a pathological condition, expressed in **stable-angina**. This is a condition where the myocardial demands exceed the coronary artery blood supply (unlike unstable angina which is a supply problem).

This is represented on the EKG as ST-segment **depression**. With ischemia of the subendocardium the ischemic cells become more positive in their resting voltage (due to channel leakage) and this makes the subendocardium more *positive*; since the endocardium is further away from the precordial leads than the more negative myocardium we see this as a depression (see figure below). Unlike elevation, the ST-segment depression is not localizable to a specific lead, but is seen in the leads with the tallest R waves, which are the inferior leads (II, III and AVF and leads V4-V6). Typically, stable angina will self-resolve, however, like elevation, the depression is increased as the myocardial demand increases. Below we see an example of ST-segment depression.

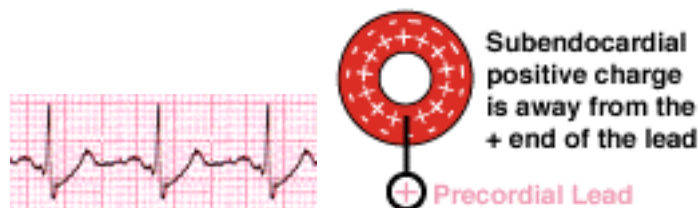


Figure 19 - ST-Segment Depression in subendocardial ischemia

Step 8

Miscellaneous

This section will deal with the miscellaneous rhythms that can present often as life threatening arrhythmias, however they don't fall into the simple categories outlined in the previous pages.

Ventricular Fibrillation

Ventricular Fibrillation (often called **V-Fib**) is the most life threatening arrhythmia, and is often the end rhythm before the **asystole** of death. The physiology of this rhythm, is a complete breakdown in the synchronization of the myocardial conduction system; different areas/cells/segments of the heart, are contracting and relaxing with no coordination with other parts. This random quivering results in a loss of cardiac output, resulting rapidly in death if untreated.

The EKG pattern of V-Fib is recognized by a total lack of organized activity, ranging from **course** (large amplitude) to **fine** (close to asystole) in amplitude. The only "cure" for V-fib is electrical cardioversion (defibrillation). However, before cardioverting a patient, remember to assure yourself, that this is actual cardiac activity, and not an artifact of patient movement (such as a seizure, shivering or Parkinson's disease), electrical interference or other artifacts. Below are examples of course and fine V-Fib.

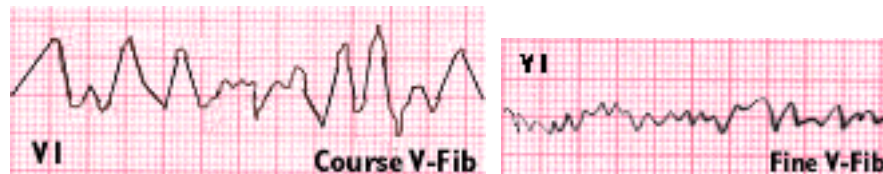

Figure 20 - Course and Fine Ventricular Fibrillation

Tachycardia

Like any other heart rhythm the origin of the signal can be either atrial or ventricular. The source of a tachycardia, if ventricular, is always pathologic, while non-ventricular tachycardias can be thought of as "sinus" and supraventricular (SVT) rhythms, and may or may not be pathologic. Pathologic tachycardias can arise from multiple causes, such as an ectopic pacemaker cell which we call abnormal automaticity, from reentry around a non-conductive block and by "triggering" by an external source.

The most common cause of pathologic tachycardias and arrhythmias results from reentry. This is due to a signal splitting around a defect and one side of that split being conducted significantly slower than the other (see below). If the slow signal meets the fast side ready to be depolarized it can cause both normal and retrograde depolarization. This can cause tachyarrhythmias due to the uncontrolled reentry.

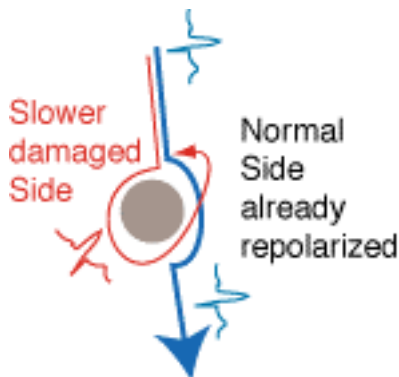


Figure 21 - Origin of reentrant arrhythmias

Sinus Tachycardia

This rhythm originates in the non-pathologic state from an increase in demand for cardiac output, which is successfully met by the heart and whose rhythm originates in the SA node. This is usually a remedy to a systemic process such as by hypovolemia, hypotension, hypoxia, nervousness, medications and exercise. Remember that if the rate is high enough, the P-wave can be obscured in the ST-segment, but is still present; this is an artifact of the EKG machine, and if you set the scanning rate higher, you can reduce this problem.

Supraventricular Tachycardias

Paroxysmal Atrial Tachycardia (PAT)

This arrhythmia is seen with reentry in the atria. There is a circular conductive pathway in the atria, causing reentry to give a rapid tachycardia. There is a single ectopic pacemaker, which can even be the AV node itself. One feature often seen with this tachycardia will be inverted P-waves, due to the source being lower down in the atria. A diagnostic procedure that can be performed to separate this from sinus tachycardia is to do vagal maneuvers, and if the rhythm slows and then resumes after cessation of the maneuvers, sinus rhythm is present. If the rhythm terminates abruptly or there's no change, then it's PAT.

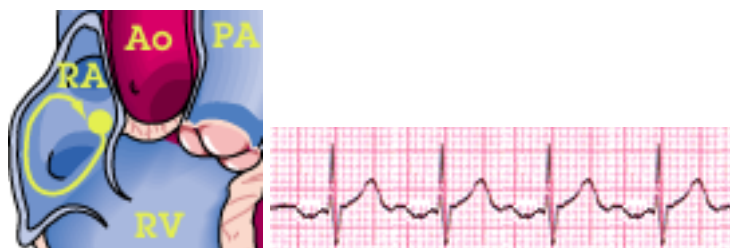

Figure 22: Paroxysmal Atrial Tachycardia

Multifocal Atrial Tachycardia (MAT)

This arrhythmia is seen with an ectopic pacemaker somewhere in the atria. The abnormal pacemaker cell, has stopped responding to the overdrive pacing from the sinus node. This causes there to be 2 or more asynchronous pacemakers for the heart. The hallmark of this form of SVT is the 2 or more P-wave morphologies you see; one P-wave from each pacemaker. Surprisingly this rhythm can often be broken by exercise or sinus-tachycardia; the reason for this, is that although the end result of MAT is tachycardia, each of the pacemakers is not tachycardia, it is the sum of their rates that produces the tachycardia. In exercise or other excitatory states, the sinus node will overdrive pace the ectopic cells.

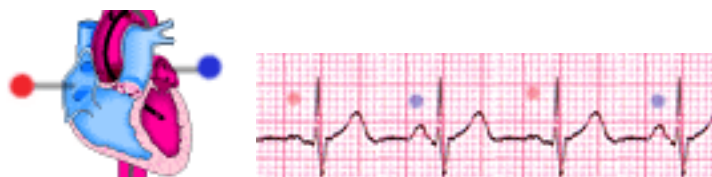

Figure 23 - Multifocal Atrial Tachycardia
Red=sinus node, Blue=ectopic

Ventricular Tachycardia

When the rhythm originates in the ventricles, the intrinsic rate or automaticity is below 60 bpm. This can be seen in idioventricular rhythms when the SA or AV node are not the functioning pacemaker of the heart. However, when there is ischemic, infarcted or necrotic conductive tissue around the bundles, there can be a **reentry** of the downward propagating depolarization, that causes the signal to repeat itself. This causes the very fast rate, as seen in **Ventricular Tachycardia** (often called V-tach); this can be a life threatening condition. The hallmark of ventricular rhythms is the **wide QRS complex**. Below we see an example of V-Tach, with a ventricular rate of 150bpm.

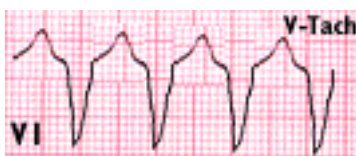

Figure 24 - Ventricular Tachycardia

Digitalis Toxicity

Digitalis is a very old cardiac drug derived from the **Foxglove** plant, used in slowing conduction through the AV node, usually in controlling the ventricular rate of atrial fibrillation. It is usually given in cases of **atrial fibrillation**. Overdoses of digitalis (either in the form of **Digoxin** or **Digitoxin**) can have effects ranging from mild 1° AV block to junctional rhythms through fatal arrhythmias. The primary mechanism of action of digitalis is to suppress the Na-K-ATPase pump; this causes the membrane potential to be more positive, allowing for easier reaching of threshold, leading to action potentials. This creates a situation where it is easy to get spontaneous action potentials, leading to arrhythmias.

The most noticeable change to the EKG is the "**swooping**" **ST-segment depression**. You also may see extended PR intervals or 1° block, although this alone is indistinguishable from primary 1° AV Block. This will also be exacerbated by hyponatremia or hyperkalemia due to the failure of the ATPase pump to reestablish a membrane potential. Below we see an example of the swooping ST-segment.

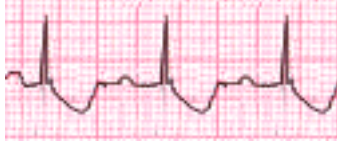

Figure 25 - Digitalis Toxicity

Hyperkalemia

Potassium (K) is one of the 2 ions that make up the bulk of the ion-based membrane potential of cardiac cells (both myocytes and conduction cells). An imbalance of potassium can create a life threatening situation which must be corrected immediately. The most prominent feature of an EKG of a hyperkalemic patient is the peaked-T wave. The other feature of the hyperkalemic EKG is a stretching of entire waveform.

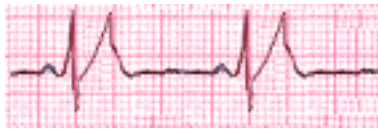

Figure 26 - Peaked-T Waves consistent with Hyperkalemia

Credits

Authors

Henry Feldman

Henry Feldman is a Medical Student in the Class of 2001 at the NYU School of Medicine. He is also a Massachusetts licensed EMT, a Nationally registered EMT as well as being ACLS certified. He is the webmaster for the NYU School of Medicine Student Organization Web Sites. He also produced all the artwork in this publication (except for the Ox-heart by Leonardo DaVinci). He is also an AHA CPR instructor. He can be reached at his [email: feldmh01@popmail.med.nyu.edu](mailto:feldmh01@popmail.med.nyu.edu)

Mariano Rey, MD

Mariano Rey, Class of 1976 at the NYU School of Medicine is the Director of the Bellevue Cardiac Clinic, Director of the NYU Cardiac Rehabilitation and Prevention Center, Director of the first-year Physiology Course, and is an associate professor of the NYU School of Medicine. He is also Director of Nuclear Cardiology and the Cardiac Stress Laboratory. He can be reached at his [email: reym01@mcdad.med.nyu.edu](mailto:reym01@mcdad.med.nyu.edu)

Other Contributors

Daniel Fisher, MD

Daniel Fisher, is a clinical instructor in the Department of Medicine, division of Cardiology. He is also the associate director of the Bellevue Stress Laboratory. He is also the Director of In-patient Services at the NYU Cardiac Rehabilitation and Prevention Center. He acted both as an editor and sounding board for parts of this publication. He can be reached at his [email: fished01@mcdad.med.nyu.edu](mailto:fished01@mcdad.med.nyu.edu)